

LASER SURGERY VERSUS NOTARAS TECHNIQUE FOR CLOSED LATERAL SPHINCTEROTOMY IN ANAL FISSURE TREATMENT: A RANDOMIZED CONTROLLED PROSPECTIVE TRIAL

Youssri Salah Eldeen Gaweesh, Mohamed Mazloun Zakaria, Ahmed Mohamed Osama Abd EL Zaher Moaz, Sally AlaaEldeen Hasan Aly

Department of Surgery, Faculty of Medicine, Alexandria University

INTRODUCTION

Anal fissure is a benign painful anorectal condition. It affects any age group but especially the young adults

The anal spasm is considered a defense mechanism to prevent more stretching of the anal canal. A closed cycle occurs when the anal spasm increase the ischemia and prevents the healing of the fissure. As long this cycle continues, the chance of spontaneous healing decreases and the fissure edges become fibrosed, which may lead to a chronic fissure.

Good history and physical examination are usually allow the diagnosis of the anal fissure.

Surgical management of anal fissure is still the best and last option for fissures which not responded well or not completely healed over 6-8 weeks.

Of all surgical options, lateral internal sphincterotomy is the treatment of choice for chronic anal fissures.

Laser Surgery for Treatment of Anal Fissure is newly introducing surgical method supposed to be a successful, easy and quick way of treating Anal Fissure.

AIM OF THE WORK

The aim of the current study was to compare the impact of the Anal fissure laser surgery Vs the Notaras closed lateral internal sphincterotomy on short term outcome including: post-operative pain, infection, incontinence, time of healing and quality of Life.

PATIENTS AND METHODS

PATIENTS: The study will include thirty patients with chronic anal fissure admitted to Alexandria main University Hospital, colorectal surgery unit.

METHODS: Group (A): (n=15) will be subjected to CLS (Notaras procedure).

Group (B): (n=15) will be subjected to laser anal fissure repair.

For Group A. Notaras closed lateral internal sphincterotomy will be done.

1-Putting of Alan-Park rectal retractor in the anus.

2-A “blind” lateral subcutaneous internal anal sphincterotomy is performed with No. 15 blade scalpel after the intersphincteric groove has been located via manual palpation of the IAS.

3-The scalpel is inserted into the intersphincteric groove to pass upwards.

4-Blade is moved medially to cut the lower 1 cm of the internal sphincter.

5- Removal of the sentinel pile if present by diathermy.

6- Good Hemostasis.

For Group B:

1-A Proctoscope is introduced to the anus.

2-Fibers of the laser are introduced in the intersphincteric plane.

3-The anal mucosa is palpated and saved by application of one finger from behind.

4-Starting to cut the internal sphincter by the laser fibers until feeling release of the sphincter fibers.

5-Removal of sentinel pile if present by the laser beam.

6-Ice packing is then applied for 1 minute.

RESULTS

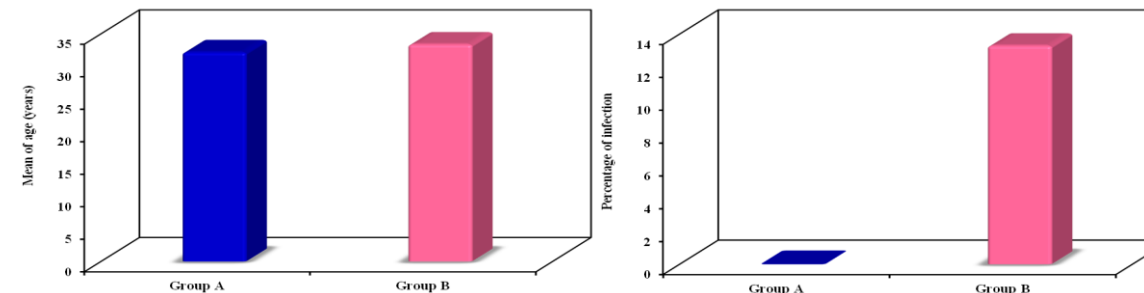


Figure 1: Comparison between the two studied groups according to the ages.

Figure 2: Comparison between the two studied groups according to infection

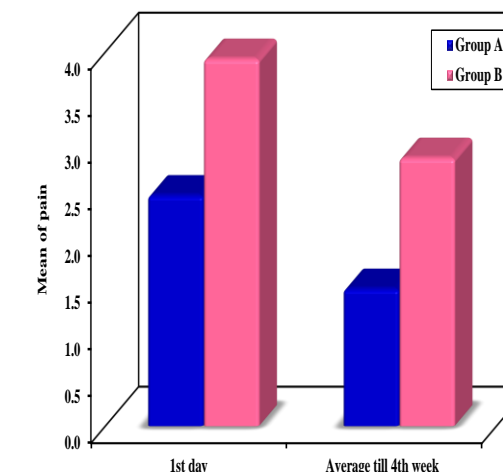


Figure 3: Comparison between the two studied groups according to pain

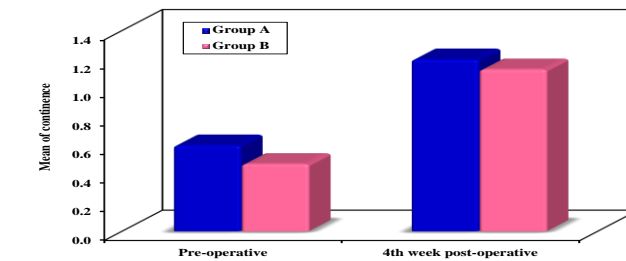


Figure 5: Comparison between the two studied groups according to continence.

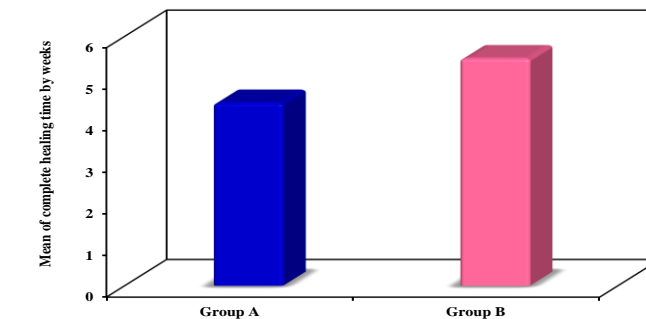


Figure 6: Comparison between the two studied groups according to complete healing.

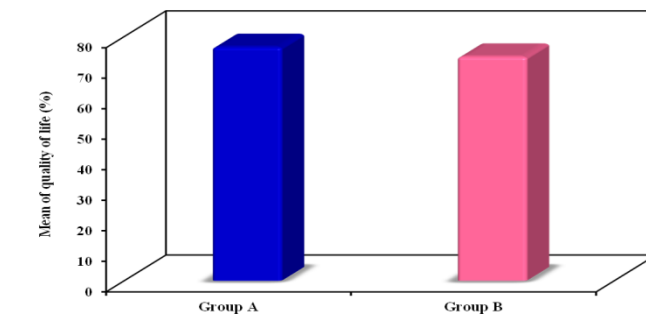


Figure 7: Comparison between the two studied groups according to quality of life.

CONCLUSION

- There was significant difference decrease in post-operative pain and time of fissure healing in NOTARAS group compared to laser group.
- There was no significant difference in post-operative infection, continence and quality of life between the two groups.
- More studies with a larger sample size are needed to confirm the results of our study.